

DOI: 10.15825/1995-1191-2022-1-31-35

# APPLICATION OF INDOCYANINE GREEN FLUORESCENCE FOR URETER IMAGING: REVIEW

A.D. Smagulov<sup>1</sup>, M.S. Rysmakhanov<sup>1, 2</sup>, Zh.M. Koishybayev<sup>1</sup>, Y.B. Sultangereyev<sup>2</sup>, N.M. Mussin<sup>1</sup>

<sup>1</sup> West Kazakhstan Medical University, Aktobe, Kazakhstan

<sup>2</sup> Department of Surgery and Transplantation, Aktobe Medical Center, Aktobe, Kazakhstan

**Introduction.** Indocyanine green has been used in medicine for more than 70 years in cardio-thoracic surgery, hepatobiliary and colorectal surgery, urology, gynecology, transplantology, etc. This review based on literature dates describing the use of ICG for intraoperative imaging and evaluation of the ureteral perfusion. **Method.** The research searched in the electronic database PubMed, Scopus, Elsevier, Springer, and Web of Science between January 2000 and December 2020, using the following search terms: ICG imaging, ureteral vessels. Additional literature data identified from separately published sources. **Results.** There are 21 articles were obtained in the specified database: 9 – with intravenous ICG, 12 – with intraureteral administration. The use of intravenous ICG followed by next clinical situation: ureteral imaging is described for ureteral strictures, for isolation and preservation of the ureteral branch of the uterine artery during radical hysterectomy, for robotic radical cystectomy with ureteroenterostomy, for laparoscopic removal of ureteral endometriosis, for evaluation of ureteral perfusion during kidney transplantation, and for identification and prevention of ureteral damage during pelvic surgery in patients with colorectal tumors and gynecological pathologies. **Conclusions.** Both intravenous and intraureteral ICG imaging are safe, easy to perform, and easily reproducible. It allows objectively identifying the degree of perfusion of the ureteral wall, clearly determining the boundaries of the stricture. It is effectively helps in the prevention of ureteral wall damage in extraurinal surgical interventions.

**Keywords:** ICG, ICG fluorescence, ureter detection.

## INTRODUCTION

Indocyanine green (ICG) has been used in clinical medicine for more than 70 years, when it was first used to assess cardiac and hepatic function [1–3]. ICG is a tricarboxyanine molecule with a half-life of 150–180 seconds, completely excreted into the bile by the liver [4]. The literature also describes the metabolism of ICG in the renal parenchyma, which occurs with the participation of the protein bilitranslocase [5]. Intravenous administration of ICG is non-toxic and effective at low doses [6]. It was also shown that ICG has an effective intraoperative contrast identifier in real time with the possibility of penetration into tissues up to 5 mm [7].

The first report on the use of ICG for perfusion evaluation of a kidney transplant was reported in 2004 [8]. In the future, this method was used to assess the blood flow of the renal parenchyma during partial nephrectomy, donor nephrectomy, and vascular anastomoses of the renal graft [9–12]. Although there are many reports on the use of ICG in urology, there are few studies on the visualization and assessment of the ureteral condition.

This review focuses on the current literature that describes the use of ICG to intraoperative visualize and evaluate the condition of the ureter.

To do this, a search was conducted for studies in the electronic database PubMed, Scopus, Elsevier, Springer and Web of Science in the period from January 2000 to December 2020, using the following search terms: “ICG imaging, ureteral”. Additional literature data were identified from separately published sources. As a result, 21 articles were received in the specified database. Of these, 9 articles describe the use of ICG imaging of the ureter with intravenous administration, 12 – with intraureteral administration.

## VISUALIZATION OF THE URETER DURING INTRAVENOUS ADMINISTRATION OF ICG

Sekijima M. et al. reported in 2004 on the use of intravenous ICG (IV-ICG) to visualize the urinary system in a kidney transplant recipient. This method made it possible to record and reproduce images of organ vessels in real time during the operation [8].

IV-ICG imaging has proven to be particularly useful in robotic surgery in cases of ureteral scar strictures. At

the same time, it allows you to completely resect the scar-altered ureteral tissue and perform ureteral reimplantation with preserved perfusion. Marc A. Bjurlin et al. 42 robotic operations for the reconstruction of the upper urinary tract were performed using this technique. At the same time, perioperative complications occurred in 14.3% of cases. The authors of this study hypothesized that the use of NIRF imaging can prevent postoperative ureteral stricture, especially during repeated operations, and also helps to ensure adequate blood flow in the area of the urinary anastomosis [13]. Although the authors indicate a lack of clinical data for long-term follow-up.

In two cases report by Ying Long et al. successful isolation and preservation of the ureteral branch of the uterine artery during radical hysterectomy with IV-ICG angiography for cervical cancer was demonstrated [14]. This procedure prevents damage to the ureteral branch with subsequent ischemia of the distal ureter leading to its necrosis and stricture. During 4 months of follow-up of these patients, there were no complications associated with the ureter.

After a robotic radical cystectomy with urinary diversion (RCUD), a severe complication is the development of ureteral anastomosis stricture. Jim K. Shen et al. conducted a comparative study of patients who underwent ureteroenterostomy in two groups of  $n = 93$  in each: with IV-ICG imaging of the ureter, and without IV-ICG [15]. In the group of patients with IV-ICG imaging with a median follow-up of 12.0 months, there was no complication from ureteroenterostomy. While in the group without IV-ICG imaging (median follow-up 24.3 months), the number of complications was 7.5% ( $p = 0.01$ ). Thus, the use of the IV-ICG method of visualization of ureteral perfusion allowed to significantly reduce the frequency of ureteroenterostomy strictures.

Another study analyzed 345 cases of ureteroenterostomy during robot-assisted radical cystectomy, of which 89 cases used IV-ICG imaging to assess vascularization of the distal ureter [16]. According to the results of this study, there was a significant decrease in the frequency of ureteral anastomosis strictures from 10.6% to 0% after IV-ICG evaluation of vascularization of the distal ureter. This highlights the clinical significance of this strategy for minimizing the complications of robot-assisted radical cystectomy.

The use of IV-ICG imaging of ureteral blood flow in open radical cystectomy with urinary diversion Chirag P. Doshi et al. studied in a group of 31 patients with 62 ureteroenteroanastomoses [17]. In the group with IV-ICG, ureteroenteroanastomosis stricture was observed in 3.2% of cases, in the group without IV-ICG – 16.7%. This study also confirms a decrease in the frequency of formation of ureteroenteroanastomosis structures when

using the IV-ICG imaging technique to assess vascularization of the distal ureter.

Diego Raimondo et al. in preliminary study was conducted in 23 women who underwent laparoscopic removal of ureteral endometriosis using ICG for intraoperative assessment of ureteral perfusion [18]. Intraoperative assessment of the degree of ureteral blood flow made it possible to optimally choose the tactics of further surgical approach after removal of the endometrioid nodule: Double J ureteral stenting – 3 patients, ureteral stenting – 2 patients. In the remaining 28 cases (90.3%), the blood flow was assessed as satisfactory (regular fluorescence) and did not require any intervention. NIR-ICG has proven to be a safe and feasible tool for assessing residual ureteral vascularization after conservative surgery for ureteral endometriosis.

Currently, there are two preliminary studies on the use of ICG to assess ureteral perfusion in kidney transplantation. In the study (preliminary experience) Vignolini G. et al. 6 recipients with robotic kidney transplantation from a living donor were included [19]. The second study, conducted by H. Boullenois et al., included 11 recipients, 10 of which were conducted from a cadaveric donor (Fig. 1) [20]. In both studies, the use of ICG visualization of ureteral perfusion did not take time, and allowed objective and reliable visualization of ureteral vascularization. However, the correlation between ICG fluorescence and postoperative complications could not be studied due to the small number of patients, which requires further larger studies.

## **VISUALIZATION OF THE URETER DURING INTRAURETHRAL ADMINISTRATION OF ICG**

Recently, intraurethral administration of ICG (IU-ICG) has been used for diagnostic purposes. The first mention in the available literature of ICG imaging with intraurethral administration describes a series of 7 patients with ureteral stricture who underwent robot-assisted reconstructive surgery [21]. Subsequently, intraoperative IU-ICG imaging was used to identify various ureteral pathologies in a larger cohort (8 and 25) of patients (Fig. 2) [22–25]. IU-ICG imaging made it possible to quickly and accurately identify the ureter, localize the level of structure with less tissue damage and protect its blood supply, and the technique itself is safe and easy to perform. This technique has been successfully used in operations on pathological kidneys [25, 26, 27].

The IU-ICG technique has been successfully used to identify and prevent ureteral damage during pelvic surgery in patients with colorectal tumors and gynecological pathologies [28–32]. Intraureteral ICG imaging was

effective for intraoperative identification of the ureter in complex gynecological and colorectal operations.

## CONCLUSION

Thus, based on the described literature review, it can be concluded that ICG imaging (both intravenous and intraureteral) is safe, simple to perform and easily reproducible. It allows you to objectively identify both the degree

of perfusion of the ureteral wall, and clearly determine the boundaries of the stricture. In case of extraurinary surgical interventions, such visualization effectively helps in the prevention of damage to the ureteral wall. Based on this, the use of ICG imaging in kidney transplant recipients will be the subject of our further study.

*The authors declare no conflict of interest.*

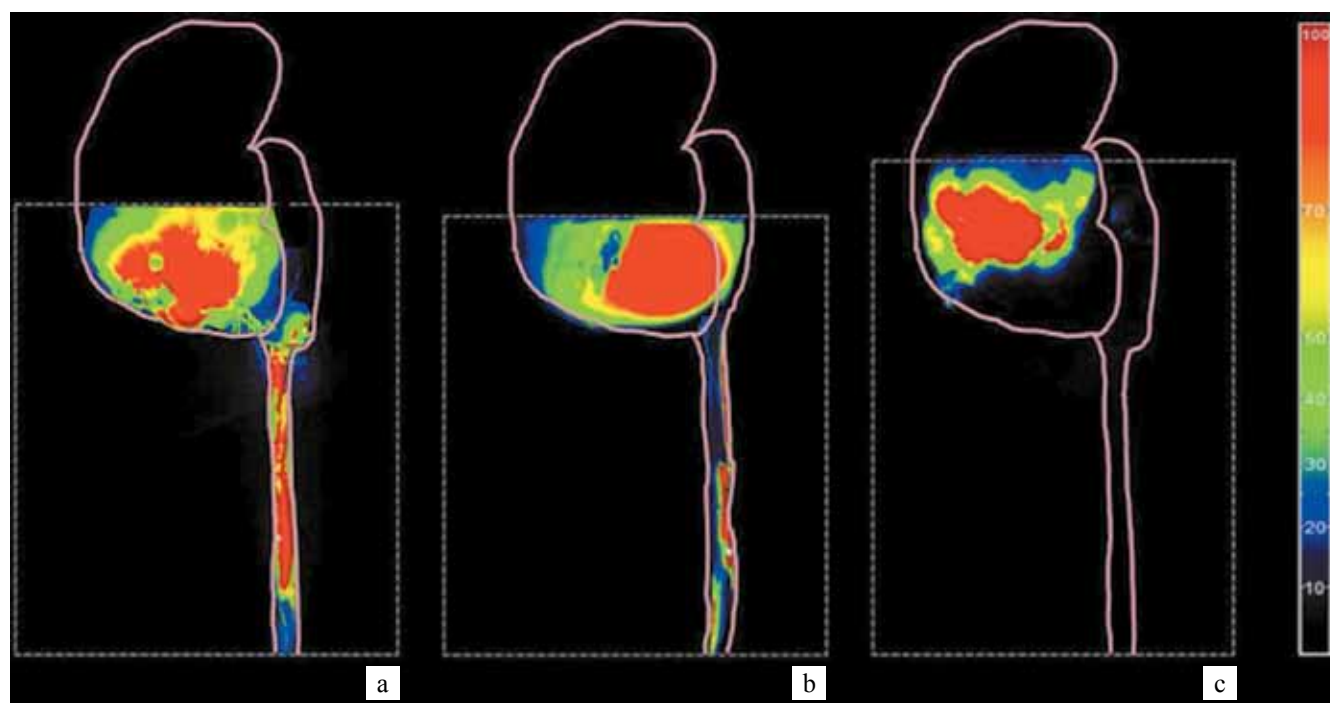

Fig. 1. Projection on a transplant diagram of an intraoperative image of indocyanin green fluorescence of a ureter in semi-quantitative analysis: a – complete and intense fluorescence of the ureter except the last centimeters in favor of good vascularization; b – partial and weak fluorescence of the ureter in favor of weak and partial vascularization; c – zero fluorescence of the ureter and the lower pole of the transplant in favor of no vascularization of the ureter and the lower pole of the transplant. Illustration: H. Boullenois et al. 2020

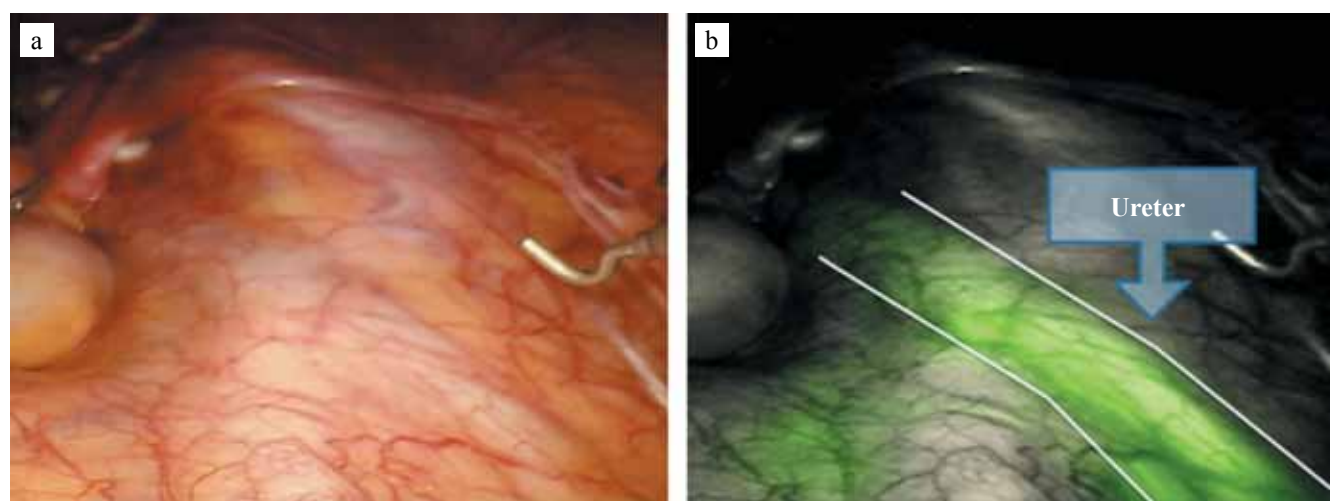


Fig. 2. Ureteral identification (a) in the absence of near-infrared fluorescence (NIRF) and (b) under NIRF. Reproduced with permission from Ziho Lee et al. 2015

## REFERENCES

1. Symposium on diagnostic applications of indicator dilution techniques. *Proceedings of the Staff Meeting of Mayo Clinic*. 1957; 32: 463–508.
2. Cherriek GR, Stein SW, Leevy CM, Davidson CS. Indocyanine green: observations on its physical properties, plasma decay, and hepatic extraction. *J Clin Invest*. 1960; 39 (4): 592–600.
3. Reinhart MB, Huntington CR, Blair LJ, Heniford BT, Augenstein VA. Indocyanine Green: Historical Context, Current Applications, and Future Considerations. *Surgical Innovation*. 2016; 23 (2): 166–175. doi: 10.1177/1553350615604053.
4. Kaplan-Marans E, Fulla J, Tomer N, Bilal K, Palese M. Indocyanine Green (ICG) in Urologic Surgery. *Urology*. 2019 Oct; 132: 10–17. doi: 10.1016/j.urology.2019.05.008. Epub 2019 May 23. PMID: 31129192.
5. Golijanin DJ, Marshall J, Cardin A, Singer EA, Wood RW, Reeder JE et al. Bilitranslocase (BTL) is immunolocalised in proximal and distal renal tubules and absent in renal cortical tumors accurately corresponding to intraoperative near infrared fluorescence (NIRF) expression of renal cortical tumors using intravenous indocyanine green (ICG). *The Journal of Urology*. 2008; 179 (4): 137. doi: 10.1016/s0022-5347(08)60394-8.
6. Majlesara A, Golriz M, Hafezi M, Saffari A, Stenau E, Maier-Hein L et al. Indocyanine green fluorescence imaging in hepatobiliary surgery. *Photodiagnosis and Photodynamic Therapy*. 2017; 17: 208–215. doi: 10.1016/j.pdpdt.2016.12.005.
7. Alander JT, Kaartinen I, Laakso A, Pätälä T, Spillmann T, Tuchin VV et al. A review of indocyanine green fluorescent imaging in surgery. *Int J Biomed Imaging*. 2012; 2012: 940585. doi: 10.1155/2012/940585. Epub 2012 Apr 22. PMID: 22577366; PMCID: PMC3346977.
8. Sekijima M, Tojimbara T, Sato S, Nakamura M, Kawase T, Kai K et al. An intraoperative fluorescent imaging system in organ transplantation. *Transplant Proc*. 2004 Sep; 36 (7): 2188–2190. doi: 10.1016/j.transproceed.2004.09.001. PMID: 15518796.
9. Tobis S, Knopf J, Silvers C, Yao J, Rashid H, Wu G, Golijanin D. Near infrared fluorescence imaging with robotic assisted laparoscopic partial nephrectomy: initial clinical experience for renal cortical tumors. *J Urol*. 2011 Jul; 186 (1): 47–52. doi: 10.1016/j.juro.2011.02.2701. Epub 2011 May 14. PMID: 21571337.
10. Boni L, David G, Mangano A, Dionigi G, Rausei S, Spampatti S et al. Clinical applications of indocyanine green (ICG) enhanced fluorescence in laparoscopic surgery. *Surg Endosc*. 2015 Jul; 29 (7): 2046–2055. doi: 10.1007/s00464-014-3895-x. Epub 2014 Oct 11. PMID: 25303914; PMCID: PMC4471386.
11. Aslim EJ, Lee FJ, Gan VHL. The Utility of Intraoperative Near Infrared Fluorescence (NIR) Imaging with Indocyanine Green (ICG) for the Assessment of Kidney Allograft Perfusion. *J Transplant*. 2018 Aug 19; 2018: 6703056. doi: 10.1155/2018/6703056. PMID: 30210867; PMCID: PMC6120275.
12. Arichi N, Mitsui Y, Ogawa K, Nagami T, Nakamura S, Hiraoka T et al. Intraoperative fluorescence vascular imaging using indocyanine green for assessment of transplanted kidney perfusion. *Transplant Proc*. 2014; 46 (2): 342–345. doi: 10.1016/j.transproceed.2013.11.129. PMID: 24655959.
13. Bjurlin MA, Gan M, McClintock TR, Volpe A, Borofsky MS, Mottrie A, Stifelman MD. Near-infrared fluorescence imaging: emerging applications in robotic upper urinary tract surgery. *Eur Urol*. 2014 Apr; 65 (4): 793–801. doi: 10.1016/j.eururo.2013.09.023. Epub 2013 Sep 27. PMID: 24099660.
14. Long Y, Yao Y, Yao DS. Indocyanine green angiography for preserving the ureteral branch of the uterine artery during radical hysterectomy: Two case report. *Medicine (Baltimore)*. 2018 Oct; 97 (40): e12692. doi: 10.1097/MD.00000000000012692. PMID: 30290662; PMCID: PMC6200471.
15. Shen JK, Jamnagerwalla J, Yuh BE, Bassett MR, Chenam A, Warner JN et al. Real-time indocyanine green angiography with the SPY fluorescence imaging platform decreases benign ureteroenteric strictures in urinary diversions performed during radical cystectomy. *Ther Adv Urol*. 2019 Apr 4; 11: 1756287219839631. doi: 10.1177/1756287219839631. PMID: 31057669; PMCID: PMC6452578.
16. Ahmadi N, Ashrafi AN, Hartman N, Shakir A, Cacciamani GE, Freitas D et al. Use of indocyanine green to minimise uretero-enteric strictures after robotic radical cystectomy. *BJU Int*. 2019 Aug; 124 (2): 302–307. doi: 10.1111/bju.14733. Epub 2019 Apr 11. PMID: 30815976.
17. Doshi CP, Wozniak A, Quek ML. Near-infrared Fluorescence Imaging of Ureters With Intravenous Indocyanine Green During Radical Cystectomy to Prevent Ureteroenteric Anastomotic Strictures. *Urology*. 2020 Oct; 144: 220–224. doi: 10.1016/j.urology.2020.06.026. Epub 2020 Jun 30. PMID: 32619603.
18. Raimondo D, Borghese G, Mabrouk M, Arena A, Ambrosio M, Del Forno S et al. Use of Indocyanine Green for Intraoperative Perfusion Assessment in Women with Ureteral Endometriosis: A Preliminary Study. *J Minim Invasive Gynecol*. 2021 Jan; 28 (1): 42–49. doi: 10.1016/j.jmig.2020.04.004. Epub 2020 Apr 10. PMID: 32283326.
19. Vignolini G, Sessa F, Greco I et al. Intraoperative assessment of ureteral and graft reperfusion during robotic kidney transplantation with indocyanine green fluorescence videography. *Minerva Urologica e Nefrologica = The Italian Journal of Urology and Nephrology*. 2019 Feb; 71 (1): 79–84. doi: 10.23736/s0393-2249.18.03278-2.
20. Boullenois H, Verrier C, Ingels A, Parier B, Serey-Eiffel S, Kozal S et al. Visualiser la vascularisation urétérale des transplants rénaux par fluorescence au vert d'indocyanine: étude exploratoire [Indocyanine green fluorescence to visualize the ureteric vascularization of kidney transplants: An exploratory study]. *Prog Urol*. 2020 Mar; 30 (3): 155–161. French. doi: 10.1016/j.purol.2020.01.005. Epub 2020 Feb 28. PMID: 32122748.

21. Lee Z, Simhan J, Parker DC, Reilly C, Llukani E, Lee DI et al. Novel use of indocyanine green for intraoperative, real-time localization of ureteral stenosis during robot-assisted ureteroureterostomy. *Urology*. 2013 Sep; 82 (3): 729–733. doi: 10.1016/j.urology.2013.05.032. PMID: 23987169.
22. Lee Z, Moore B, Giusto L, Eun DD. Use of indocyanine green during robot-assisted ureteral reconstructions. *Eur Urol*. 2015 Feb; 67 (2): 291–298. doi: 10.1016/j.eururo.2014.08.057. Epub 2014 Sep 12. PMID: 25220372.
23. Lee Z, Sterling ME, Keehn AY, Lee M, Metro MJ, Eun DD. The use of indocyanine green during robotic ureteroenteric reimplantation for the management of benign anastomotic strictures. *World J Urol*. 2019 Jun; 37 (6): 1211–1216. doi: 10.1007/s00345-018-2493-2. Epub 2018 Sep 18. PMID: 30229414.
24. Huang BW, Wang J, Zhang P, Li Z, Bi SC, Wang Q et al. Application of indocyanine green in complex upper urinary tract repair surgery. *Beijing Da Xue Xue Bao Yi Xue Ban*. 2020 Aug 18; 52 (4): 651–656. Chinese. doi: 10.19723/j.issn.1671-167X.2020.04.010. PMID: 32773795; PMCID: PMC7433627.
25. Morozov AO, Alyaev YG, Rapoport LM, Tsarichenko DG, Bezrukov EA, Butnaru DV, Sirota ES. Near-Infrared Fluorescence with Indocyanine Green for Diagnostics in Urology: Initial Experience. *Urologia Journal*. 2017; 84 (3): 197–202. doi: 10.5301/uj.5000235.
26. Lee M, Lee Z, Eun D. Intraureteral and intravenous indocyanine green to facilitate robotic partial nephroureterectomy in a patient with complete ureteral triplication. *Korean J Urol*. 2015 Jun; 56 (6): 473–476. doi: 10.4111/kju.2015.56.6.473. Epub 2015 May 27. PMID: 26078846; PMCID: PMC4462639.
27. Kanno T, Takahashi T, Somiya S, Ito K, Higashi Y, Yamada H. Indocyanine Green Fluorescence-Guided Laparoscopic Lower-Pole Heminephrectomy for Duplex Kidney in Adult. *J Endourol Case Rep*. 2020 Dec 29; 6 (4): 384–387. doi: 10.1089/cren.2020.0123. PMID: 33457680; PMCID: PMC7803210.
28. Siddighi S, Yune JJ, Hardesty J. Indocyanine green for intraoperative localization of ureter. *Am J Obstet Gynecol*. 2014 Oct; 211 (4): 436.e1-2. doi: 10.1016/j.ajog.2014.05.017. Epub 2014 May 14. PMID: 24835212.
29. Santi C, Casali L, Franzini C, Rollo A, Violi V. Applications of indocyanine green-enhanced fluorescence in laparoscopic colorectal resections. *Updates Surg*. 2019 Mar; 71 (1): 83–88. doi: 10.1007/s13304-018-00609-w. Epub 2018 Dec 3. PMID: 30511261.
30. Mandovra P, Kalikar V, Patankar RV. Real-Time Visualization of Ureters Using Indocyanine Green During Laparoscopic Surgeries: Can We Make Surgery Safer? *Surg Innov*. 2019 Aug; 26 (4): 464–468. doi: 10.1177/1553350619827152. Epub 2019 Feb 8. PMID: 30734638.
31. White LA, Joseph JP, Yang DY, Kelley SR, Mathis KL, Behm K, Viers BR. Intraureteral indocyanine green augments ureteral identification and avoidance during complex robotic-assisted colorectal surgery. *Colorectal Dis*. 2021 Mar; 23 (3): 718–723. doi: 10.1111/codi.15407. Epub 2020 Nov 5. PMID: 33064915.
32. Kamada T, Nakaseko Y, Yoshida M, Kai W, Takahashi J, Nakashima K et al. Indocyanine green fluorescence-guided laparoscopic colorectal cancer surgery with prophylactic retrograde transileal conduit ureteral catheter placement after previous total cystectomy: a case report. *Surg Case Rep*. 2021 Mar 12; 7 (1): 67. doi: 10.1186/s40792-021-01153-3. PMID: 33710480; PMCID: PMC7954966.

The article was submitted to the journal on 2.11.2021